

An audit of liquid-based cervical cytology screening samples (ThinPrep and SurePath) reported as glandular neoplasia

S. A. Thiryayi, J. Marshall and D. N. Rana

Manchester Cytology Centre, Manchester Royal Infirmary, Manchester, UK

Accepted for publication 7 July 2009

S. A. Thiryayi, J. Marshall and D. N. Rana

An audit of liquid-based cervical cytology screening samples (ThinPrep and SurePath) reported as glandular neoplasia

Objectives: The aims of this study were to assess the number of cases diagnosed as glandular neoplasia (national report code 6) of cervical (6A) and non-cervical (6B) types on ThinPrep (TP) and SurePath (SP) liquid-based cytology (LBC) samples and to calculate the positive predictive value (PPV) of these diagnoses for significant glandular and/or squamous pathology for local audit and as a contribution to national data on glandular neoplasia.

Methods: A computerized search identified all screening LBC samples reported as glandular neoplasia during the 24-month period from January 2006 to December 2007. Corresponding histology samples were identified, with a minimum follow-up period of 6 months for each case.

Results: A total of 70 samples, representing 70 patients, were reported as glandular neoplasia, 39 TP (55.7%) and 31 SP (44.3%), with 46 samples (31 TP, 15 SP) reported as 6A and 24 samples (eight TP, 16 SP) as 6B. PPV of glandular neoplasia was calculated for a biopsy diagnosis of cervical glandular intraepithelial neoplasia/adenocarcinoma and/or cervical intraepithelial neoplasia (CIN) 2 or worse. The PPV of 6A was 100% for both TP and SP. The PPV of 6B for adenocarcinoma was 62.5% for TP and 66.7% for SP. The combined PPV for 6A + 6B was 92.3% for TP, 83.3% for SP and 88.4% combined. **The overall pick-up rates for the two methods were significantly different (TP 0.031%, SP 0.052%; $P = 0.014$).** Histology showed only CIN3 with endocervical crypt involvement in nine TP cases and one SP case.

Keywords: cervical glandular intraepithelial neoplasia, adenocarcinoma, cervical intraepithelial neoplasia, liquid-based cytology, cervical screening, audit

Introduction

Glandular neoplasia of the cervix, although less common than squamous neoplasia, is increasing in incidence, resulting in increased pressure on cytopathologists and histopathologists to distinguish accurately between these two groups of abnormalities due to the different management required for each. The objectives of this audit were:

1. To assess the number of cases diagnosed as glandular neoplasia of cervical and non-cervical types on ThinPrep (TP) and SurePath (SP) liquid-based cytology (LBC) samples.
2. To identify any differences in the reporting profiles between TP and SP samples.
3. To calculate the positive predictive value (PPV) of a diagnosis of cervical glandular neoplasia for cervical glandular intraepithelial neoplasia (CGIN)/adenocarcinoma and/or significant squamous abnormality. The latter was taken to be cervical intraepithelial neoplasia (CIN) grade 2 or worse.

Correspondence:

Sakinah A. Thiryayi, MBChB, Manchester Cytology Centre, Manchester Royal Infirmary, Oxford Road, Manchester M13 9WL, UK

Tel.: +44 161 276 5111; Fax: +44 161 276 5149;

E-mail: sakinah.a.t@hotmail.co.uk

Methods

A retrospective audit was conducted in which a list of cervical cytology samples diagnosed as 'glandular

neoplasia' was generated from the computerized database of the Manchester Cytology Centre (MCC) covering the 24-month period from January 2006 to December 2007. The national standard reporting code in use in the National Health Service Cervical Screening Programme (NHSCSP) is 6 for '?glandular neoplasia'. The local coding practice is to use 6A for cervical glandular neoplasia (urgent referral to colposcopy clinic), 6B for non-cervical glandular neoplasia (urgent referral to gynaecology clinic) and 6NOS where no specific type is recorded. Cases with borderline glandular abnormalities, corresponding to atypical glandular cells in the Bethesda system, were excluded. Only screening samples obtained in primary care (general practice and community clinics) were included. Samples from symptomatic patients, taken at hospital colposcopy and gynaecology clinics, were excluded. Cases with corresponding histology reports were identified with at least a 6-month follow-up period from cytology to histology for all cases. We defined as the pick-up rate the number of cases reported as glandular neoplasia (6A and/or 6B) that had a significant glandular and/or squamous abnormality on histology as a proportion of the total number of adequate screening samples. Fisher's exact test was used to determine statistical significance.

abnormal during this time, 9027 (76.2%) TP and 2820 (23.8%) SP.

Samples reported as 6A—cervical glandular neoplasia

There were 46 samples in this group (31 TP, 15 SP). The mean age for a 6A sample was 35.1 years (range 23–59 years). The corresponding histology samples comprised cervical punch biopsies alone ($n = 4$), large loop excisions of the transformation zone (LLETZ) ($n = 26$), cervical cone biopsies ($n = 14$) and hysterectomy specimens ($n = 2$). Adequate histology samples were available for all cases. The correlation between cytology and histology diagnoses is shown in Table 1 with glandular histology diagnoses comprising CGIN/cervical adenocarcinoma and squamous histology diagnoses comprising CIN2 or worse.

It can be seen that proportionately more SP samples reported as 6A showed a corresponding glandular abnormality on histology, with ten of the TP samples showing only a squamous abnormality on histology. In nine of these cases there was high-grade CIN (CIN2 and/or CIN3) involving endocervical crypts. This finding occurred in only one of the SP samples.

The PPV (Table 2) was calculated in each case using the NHSCSP definition.

$$\text{PPV} = \frac{\text{Number with outcome of CIN2, CIN3, adenocarcinoma in situ or carcinoma}}{\text{Number reported as code 6 with known outcome, adequate histology and colposcopy}} \times 100\%$$

Results

A total of 70 samples, representing 70 patients, were reported as '?glandular neoplasia', of which 39 (55.7%) were TP and 31 (44.3%) SP with 46 samples (65.7%) reported as glandular neoplasia of cervical type (6A) and 24 samples (34.3%) as non-cervical type glandular neoplasia (6B). One sample was reported as 6NOS, which proved to be of cervical type and has been included in this category for analysis. The mean age for a glandular neoplasia sample was 42.0 years (range 23–73 years). During the 2-year audit period, a total of 165 130 adequate screening cervical cytology samples were reported at the MCC, of which 71.0% were TP (117 226) and 29.0% SP (47 904). The 70 samples included in this audit represent 0.042% of the total number of adequate screening samples. A total of 11 847 (7.2%) screening samples were reported as

Although the overall PPV for any significant abnormality was 100% for both LBC methods, it can be seen that the PPV for glandular abnormalities, with or

Table 1. Correlation between cytology and histology diagnoses (46 cases reported as 6A cervical glandular neoplasia)

Histology	Cytology glandular only ($n = 18$)		Cytology glandular and squamous ($n = 28$)	
	ThinPrep	SurePath	ThinPrep	SurePath
Glandular*	7	5	2	2
Glandular and squamous†	2	1	10	6
Squamous	3	0	7	1
Negative	0	0	0	0

*Cervical glandular intraepithelial neoplasia, adenocarcinoma *in situ* or adenocarcinoma.

†Cervical intraepithelial neoplasia grade 2 or worse.

Table 2. Positive predictive value (PPV) according to liquid-based cytology method for samples reported as glandular neoplasia of cervical type (6A)

	ThinPrep	SurePath	Total
Total samples reported as 6A	31	15	46
Total samples confirmed histologically as CGIN/cervical adenocarcinoma only	9	7	16
PPV for CGIN/cervical adenocarcinoma (%)	29.0	46.7	34.8
Total samples confirmed histologically as CGIN/cervical adenocarcinoma with ≥ CIN2	12	7	19
PPV for CGIN/cervical adenocarcinoma with or without ≥ CIN2 (%)	67.7	93.3	76.1
Total samples confirmed histologically as ≥ CIN2 (squamous abnormality only)	10	1	11
PPV for CGIN/cervical adenocarcinoma and/or squamous abnormality (%)	100	100	100

CGIN, cervical glandular intraepithelial neoplasia; CIN, cervical intraepithelial neoplasia.

without squamous abnormalities, was higher for SP compared with TP.

Samples reported as 6B—non-cervical glandular neoplasia

There were 24 samples in this group (eight TP, 16 SP). The mean age for a 6B sample was 55.3 years (range 45–73 years). The corresponding histology samples comprised varying combinations of cervical punch biopsies ($n = 3$), LLETZ ($n = 5$), endometrial biopsies ($n = 15$) and hysterectomy specimens ($n = 7$). Cervical specimens alone were not considered as adequate samples for investigation of possible non-cervical glandular neoplasia. Adequate histology specimens were available for 23 of the cases, with one SP case excluded due to an inadequate endometrial biopsy. Further clinical follow-up information was not available for this case and hence it has been excluded from PPV calculations, although it should be noted that an inadequate biopsy may be expected from an atrophic endometrium, and a concomitant lack of endometrial thickening on transvaginal ultrasound may be sufficient to exclude cancer.¹ The PPV for each LBC method is shown in Table 3.

There were 15 cases that proved to be adenocarcinoma on histology, 14 of which were endometrial in

Table 3. Positive predictive value (PPV) according to liquid-based cytology method for samples reported as glandular neoplasia of non-cervical type

	ThinPrep	SurePath	Total
Total samples reported as 6B with adequate histology	8	15	23
Total samples confirmed histologically as adenocarcinoma	5	10	15
PPV for adenocarcinoma, (%)	62.5	66.7	65.2

origin. One of the SP cases was an advanced-stage cervical adenocarcinoma, confirmed on cervical biopsy. The histology of three of the TP cases failed to confirm neoplasia. One of these cases was reported histologically as an inflamed endometrial polyp and review of the cytology was consistent with this diagnosis. The other two cases showed no significant pathological abnormality. There were five SP samples for which histology failed to confirm carcinoma. Three of these were negative, one showed papillary endocervicitis and the remaining one showed features in keeping with the presence of an intrauterine contraceptive device on cytological review.

Overall results for samples reported as 6A and 6B

An amalgamation of the results for cervical and non-cervical type glandular neoplasia is presented in Table 4, with an overall PPV of samples reported as glandular neoplasia, for a significant glandular and/or squamous lesion, of 88.4%.

The overall glandular neoplasia (6A + 6B) pick-up rate for TP was 0.031% and 0.052% for SP. This is illustrated in Figure 1, as well as the number of cases of glandular neoplasia as a proportion of the total number of abnormal screening samples. The difference between these proportions was found to be statistically significant [$P = 0.014$, 95% confidence interval (CI)]. When analysed separately as cervical and non-cervical type glandular neoplasia, there was a statistically significant difference in pick-up rate for 6B, which was 0.004% with TP and 0.021% with SP ($P = 0.002$, 95% CI). The difference for 6A did not achieve statistical significance, where the TP pick-up rate was 0.026%, versus 0.031%, with SP ($P = 0.108$, 95% CI).

Discussion

The nationally calculated PPVs of laboratories participating in the NHSCSP for 2006/2007 ranged from 52

Table 4. Positive predictive value (PPV) according to liquid-based cytology method for samples reported as glandular neoplasia of cervical (6A) and non-cervical (6B) types

	ThinPrep	SurePath	Total
Total samples reported as 6A and 6B	39	31	70
Total samples reported as 6A and 6B with adequate histological sample	39	30	69 (98.6%)
Total samples confirmed histologically as CGIN/adenocarcinoma with/without squamous abnormality	26	24	50
PPV for CGIN/adenocarcinoma with/without squamous abnormality (%)	66.7	80.0	72.5
Total samples confirmed histologically as \geq CIN2 (squamous abnormality alone)	10	1	11
PPV for squamous abnormality alone (%)	25.6	3.3	15.9
Total samples confirmed histologically as CIN2 or worse	36	25	61
PPV for CGIN/adenocarcinoma and/or squamous abnormality (%)	92.3	83.3	88.4

CGIN, cervical glandular intraepithelial neoplasia; CIN cervical intraepithelial neoplasia.

to 94% for adequate cervical samples reported as moderate dyskaryosis or worse for CIN2 or worse, with the majority in the 70.5–86.4% range.² According to national statistics,² for the 2006/2007 year the MCC PPV for TP and SP combined was 80.6% (April 2005 to March 2006). The total PPVs of the MCC calculated in this audit for samples reported as glandular neoplasia only are at the top end of the overall national range, which includes both squamous and glandular abnormalities, for both TP (92.3%) and SP (83.3%).

Although the workload at the MCC is approximately 70% TP, and screening with TP started prior to introduction of SP, in this study the overall pick-up rate for glandular neoplasia (cervical and non-cervical type) was significantly better in SP (0.052%) as opposed to TP (0.031%) (Figure 1). The difference in

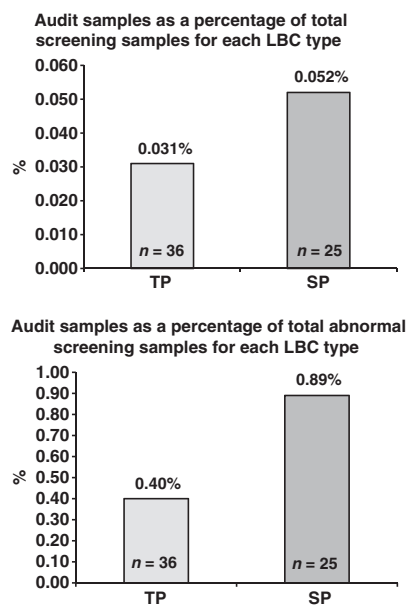


Figure 1. Comparison of percentage of 'glandular neoplasia' samples with significant histological abnormality as a percentage of total screening samples and total abnormal screening samples for each liquid-based cytology (LBC) type.

preparation for each LBC method may partially account for the differences in pick-up rates between the two LBC methods and could be the subject of further study. The TP method does not retain the sampling device and uses a filtration technique, whereas the SP method retains the sampling device in the vial and uses density gradient centrifugation to prepare the final slide. In our experience, the cellular presentation of cervical glandular neoplasia appears better in SP. Another possible factor is the difference in cytological features of glandular neoplasia between the two methods, with TP samples having been reported as showing greater similarity to conventional smears (CS) than SP.³ Single dyskaryotic cells and large groups (more than 20 cells) showing crowding and overlapping have been noted to be less frequent in TP.⁴ Short pseudostratified strips, with fanning out of bulging nuclei, is seen particularly in SP samples.⁵ With regard to cervical glandular neoplasia, the lower number of TP cases may be due to CGIN and adenocarcinoma being miscategorized as squamous abnormalities or even being missed at screening. These possibilities will be assessed in another audit in which a list of histology samples reported as CGIN or adenocarcinoma of the cervix will be compiled and correlated with the reports of the preceding cytology

samples (TP and SP), with review of the cytology slides in discrepant cases.

A review of screening CS reported as glandular neoplasia at the MCC for the 24-month period from January 2004 to December 2005 yielded a total of 40 samples, one of which did not have adequate histology. For 6A and 6B diagnoses combined the PPV for CGIN/adenocarcinoma was 51.3%, and for CIN2 or worse the PPV was 82.1% (unpublished observations). The total number of screening samples during this time period was 121 916, with a pick-up rate of 0.026% for cases reported as glandular neoplasia that showed a significant glandular or squamous abnormality on histology. This rate is lower than that found for both LBC methods in the current audit, possibly reflecting an increased awareness and diagnosis of glandular abnormalities, better sampling of the endocervix with LBC broom devices and an increasing incidence⁶ of cervical glandular abnormalities.

The implementation of LBC for cervical screening is still relatively recent, and although there are some publications available for comparison with the results of this audit, most relate to CS and TP samples. Mathers *et al.*⁷ reported a PPV of abnormal glandular cytology on CS of 55.7% for a significant glandular abnormality and 72.7% for a significant glandular and/or squamous abnormality, although this study included screening and colposcopy samples. A study comparing the accuracy of a diagnosis of atypical glandular cells on CS and TP samples, equivalent to borderline abnormalities and glandular neoplasia in the NHSCSP terminology, found PPVs of 42.6 and 58.9%, respectively, for all significant lesions with PPVs of 28.8 and 50.9%, respectively, for purely glandular significant abnormalities.⁸ The abnormalities regarded as significant are not clearly defined, however, and appear to include borderline and low-grade types, reducing comparability with the current audit. Another audit of glandular abnormalities on CS reported PPVs for a significant histological abnormality of 80.6% in the CGIN smear group and 86.1% in the endometrial adenocarcinoma group.⁹ However, both screening and symptomatic cases were included, in addition to the inclusion of CIN1 in the calculation of the PPVs, again reducing comparability. Wilson and Jones¹⁰ reported on an audit of atypical glandular cells in CS and included all grades of CIN, CGIN or endometrial hyperplasia as significant and proposed a three-tier reporting system. Patel *et al.* compared conventional cervical cytology and SP for the detection of endometrial carcinoma. In those

cases considered diagnostic of endometrial carcinoma on cytology, the PPVs were 55.4 and 73.3%, respectively.¹¹ These figures are comparable to the non-cervical PPVs in this study and, in our experience, it is possible to distinguish endocervical and endometrial adenocarcinoma in the majority of cases, using both LBC methods.

Conclusion and recommendations

Overall, in this audit, the combined PPV of both methods for significant glandular and/or squamous abnormalities was high (88.4%). Borderline glandular abnormalities were not included in this audit and the high PPV may reflect a tendency to give a cytological diagnosis of glandular neoplasia only when there is a high degree of diagnostic certainty. The results of this audit indicate that the overall pick-up rate of glandular and/or squamous abnormalities in SP samples diagnosed as glandular neoplasia was significantly greater than for TP. In addition, CIN with crypt involvement alone was diagnosed as a possible glandular abnormality in nine TP samples compared with only one SP sample. This is a pitfall encountered during the learning curve of conversion to LBC. In order to assess the difference in rates of misinterpretation of this type between the two methods, a study to attempt categorization of the cytological features of CGIN versus CIN with crypt involvement in TP and SP was undertaken to assess this finding further.¹² Furthermore, a further audit is planned to determine whether some cases of glandular neoplasia are being miscategorized or missed, particularly in TP. Borderline glandular abnormalities should also be audited to determine the final outcome of this small subgroup and an assessment of morphological features undertaken.

As noted by Wilson and Jones,¹⁰ increased publication of national data on glandular neoplasia is required for assessment of performance in detecting these lesions. However, in order to facilitate meaningful comparisons, there should be an attempt at national conformity in the definition of what constitutes a significant glandular or squamous abnormality on histology for use in calculation of PPVs.

References

1. Scottish Intercollegiate Guidelines Network. *Investigation of Post-Menopausal Bleeding*. A National Clinical Guideline. Edinburgh:: Scottish Intercollegiate Guidelines Network; 2002.

2. NHS Health and Social Care Information Centre. *Cervical Screening Programme Bulletin*. Leeds: NHS Health and Social Care Information Centre; 2006-07.
3. Johnson J. Atypical glandular cells NOS and endocervical adenocarcinoma *in situ*. In: *ThinPrep Pap Test Morphology reference Atlas*. Werneke S, Brahm C (eds). Boxborough: Cytec; 2003:84–97.
4. Belsley NA, Tambouret RH, Misdraji J *et al*. Cytologic features of endocervical glandular lesions: comparison of SurePath, ThinPrep, and conventional smear specimen preparations. *Diagn Cytopathol* 2008;**36**:232–7.
5. Waddell C. Glandular prediction: the liquid revolution. *Scan* 2007;**18**:5–11.
6. Vizcaino AP, Moreno V, Bosch FX *et al*. International trends in the incidence of cervical cancer: adenocarcinoma and adenosquamous cell carcinoma. *Int J Cancer* 1998;**75**:536–45.
7. Mathers ME, Johnson SJ, Wadehra V. How predictive is a cervical smear suggesting glandular neoplasia? *Cytopathology* 2002;**13**:83–91.
8. Ramsaroop R, Chu I. Accuracy of diagnosis of atypical glandular cells—Conventional and ThinPrep. *Diagn Cytopathol* 2006;**34**:614–9.
9. Kirwan JM, Herrington CS, Smith PA, Turnbull LS, Herod JJO. A retrospective clinical audit of cervical smears reported as 'glandular neoplasia'. *Cytopathology* 2004;**15**:188–94.
10. Wilson C, Jones H. An audit of cervical smears reported to contain atypical glandular cells. *Cytopathology* 2004;**15**:181–7.
11. Patel CJ, Ullal A, Roberts M *et al*. Endometrial carcinoma detected with Surepath liquid based cervical cytology: comparison with conventional cervical cytology. *Cytopathology* 2006;**17**(Suppl 1):20–20.
12. Thiryayi SA, Marshall J, Rana DN. Differentiating between endocervical glandular neoplasia and high grade squamous intraepithelial lesions in endocervical crypts: cytological features in ThinPrep and SurePath cervical cytology samples. *Diagn Cytopathol* 2009;**37**:315–9.